

# Disseminated Cerebral and Intradural Extramedullary Spinal Nocardiosis in an Immunocompetent Patient

Meenal Sharma<sup>1</sup>, Chris Anthony<sup>2</sup>, Charlie Chia-Tsong Hsu<sup>1</sup>, Catriona Maclean<sup>3</sup>, Niki Maartens<sup>4</sup>

<sup>1</sup>Department of Medicine, Alfred Hospital, Melbourne, Victoria, Australia

<sup>2</sup>Department of Cardiology, St Vincent's Hospital, Sydney, Australia

<sup>3</sup>Department of Anatomical Pathology, Alfred Hospital, Melbourne, Victoria, Australia

<sup>4</sup>Department of Neurosurgery, Alfred Hospital, Melbourne, Victoria, Australia

Doi: 10.12890/2015\_000207 - European Journal of Case Reports in Internal Medicine - © EFIM 2015

Received: 07/04/2015

Accepted: 15/05/2015

Published: 02/07/2015

**How to cite this article:** Sharma M, Anthony C, Hsu CC-T, Maclean C, Maartens C. Disseminated cerebral and intradural extramedullary spinal nocardiosis in an immunocompetent patient. *EJCRIM* 2015;2:doi: 10.12890/2015\_000207

**Conflicts of Interests:** The authors declare that they have no conflicts of interest in this research.

**Acknowledgements:** The authors declare they had patient's permission for reporting this case report.

This article is licensed under a [Commons Attribution Non-Commercial 4.0 License](#)

## ABSTRACT

Disseminated nocardiosis of the central nervous system (CNS) has been rarely reported, especially in the immunocompetent patient. We report a case of cerebral and cervical intradural extramedullary nocardiosis likely to have been the result of disseminated spread from a pulmonary infective focus. Attempts at tissue biopsy and culture of the initial cerebral and pulmonary lesions both failed to yield the diagnosis. Interval development of a symptomatic intradural extramedullary cervical lesion resulted in open biopsy and an eventual diagnosis of nocardiosis was made. We highlight the diagnostic dilemma and rarity of spinal nocardial dissemination in an immunocompetent individual.

## LEARNING POINTS

- Disseminated nocardiosis can occur in immunocompetent patients.
- Systemic manifestations of sepsis suggested an infective aetiology.
- When disseminated lesions are found, tissue diagnosis is vital in directing management; in this case, biopsies were taken from both thoracic and spinal lesions.

## KEYWORDS

Nocardiosis, immunocompetent, central nervous system, spinal cord, magnetic resonance imaging.

## INTRODUCTION

Nocardia is an aerobic Gram-positive branching, filamentous bacillus that is found in soil. It is acquired through either direct inoculation or, more commonly, inhalation. Nocardia often presents as an opportunistic infection in immunocompromised patients. The predisposed population includes post-organ transplantation patients on immunosuppression therapy, patients with acquired immune deficiency syndrome (AIDS) and patients on chronic steroid therapy<sup>[1-6]</sup>. Cerebral nocardia infection is rare and accounts for only 1-2% of all cerebral abscesses. Even rarer is spinal dura and/or medullary involvement, with only a handful of confirmed cases reported in the literature. Central nervous system (CNS) nocardia infection is notoriously difficult to diagnose as presenting symptoms are non-specific and dependent on the anatomical location of the lesion. Previously reported symptoms include headaches, visual disturbances, ataxia, seizures, focal neurological deficits and myelopathy<sup>[5,6]</sup>. Only through biopsy of the lesion and culture can early identification of the organism be made and proper antimicrobial therapy instituted. We highlight a rare case of disseminated CNS nocardiosis and discuss the diagnostic dilemma before a final diagnosis was reached.

## CASE REPORT

A 77-year-old male presented with a 3-month history of headache, poor concentration, short-term memory deficits and unsteady gait. His past medical history was significant for a recent diagnosis of prostate cancer. The patient underwent staging scans. A CT of the chest demonstrated a cavitory lesion in the right upper lobe with surrounding ground-glass opacity (*Fig. 1*). No focal neurological deficit was found on physical examination. The initial differential diagnoses of the pulmonary lesion were primary lung malignancy, pulmonary metastases from prostate cancer, and reactivation tuberculosis. Differential diagnoses for the cerebral lesion were cerebral metastases from prostate cancer and abscess.

During admission the patient became febrile with a temperature of 39.7°C. Laboratory investigations revealed an elevated white cell count of 23.30 with neutrophilia 20.90 and a C-reactive protein of 100. Blood cultures, sputum cultures and cerebrospinal fluid (CSF) cultures from a lumbar puncture were all negative. Blood and sputum cultures for acid-fast bacilli were also negative. MRI of the brain to further characterize the cerebral lesion showed a 1.1×1.1 cm (Fig. 2) peripherally enhancing subependymal mass adjacent to the body of the left ventricle. It had a peripheral low signal rim with central restricted diffusion on T2 images. The surrounding vasogenic oedema was out of keeping with the size of the lesion. A transthoracic echocardiogram was unremarkable.

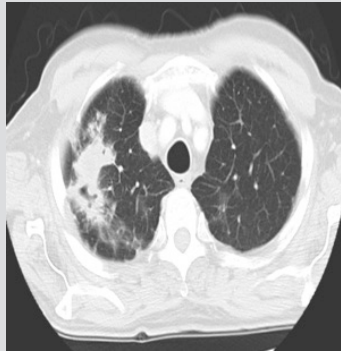


Figure 1: CT of the chest showing nocardial focus.

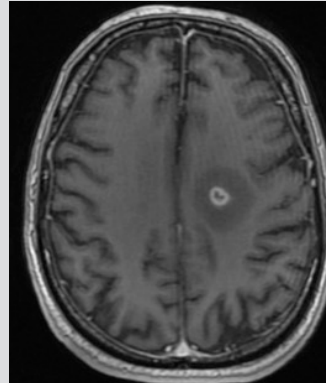


Figure 2: T1 weighted MRI of the brain showing nocardial abscess

Tests for human immunodeficiency virus (HIV), human T lymphotropic (HTC) virus, syphilis, Bartonella, histoplasmosis, Cryptococcus, toxoplasmosis, Entamoeba and Strongyloides were all negative. A vasculitic screen was also negative. A full immunology panel was performed and failed to demonstrate underlying immunodeficiency. The patient had a normal lymphocyte count of  $1.49 \times 10^9$ , B cell surface markers were 10.1, total memory B cells 1.8%, IgM memory B cells 1.1% lymph and B cells 11.1%. CD19+ B cells were 80/ $\mu$ l. Total B cells were 65.4%, and switched memory cells were 0.6% lymph. His T cell marker lymphocyte count was  $0.74 \times 10^9$ , CD3 76%, CD3+ count 562/ $\mu$ l, %CD3+/CD4+ count 43/ $\mu$ l and CD3+/CD4+ count 415/ $\mu$ l.

CT-guided tissue biopsy and video-assisted thoracoscopy (VATS) of the right upper lobe lesion were both inconclusive. Tissue histology showed necrosis and features of acute or chronic inflammation. Cultures for acid-fast bacilli and mycobacterial polymerase chain reaction were negative. Stereotactic biopsy of the cerebral lesion again revealed a reactive inflammatory process, with negative cultures. After an exhaustive battery of tests, the patient had made clinical improvements. He was discharged home on broad spectrum oral antibiotics and trimethoprim.

However, 1 month after discharge, the patient represented to the hospital with neck pain and cervical myelopathy. Neurological examination demonstrated reduced muscle power (3/5) in the C5, C6 and C7 myotome bilaterally. He also demonstrates hyperreflexia, hypertonicity and clonus in both upper and lower limbs. MRI of the spine revealed a 10 mm dural-based enhancing mass lesion at the level of C4–C6 spinal cord with hyperintensities at the corresponding level. Urgent C4–C6 decompressive laminectomy and excision of the cervical intradural lesion were performed. Intra-operatively, abnormally thickened tissue was seen in the underlying dura at C3–C6. Histopathological analysis of the tissue sample revealed inflammatory cell infiltrate comprising of multinucleate giant cells and chronic inflammatory cells including plasma cells and lymphocytes and histiocytes in association with scattered neutrophils. Reactive fibroblasts were also seen alongside ill-formed granulomata. Active granulomatous inflammation was diagnosed and, with special staining, linear long bacillary structures within which were clusters of neutrophils, were seen and the diagnosis of nocardiosis was made.

Post-operatively the patient was commenced on meropenem and trimethoprim. He made a slow neurological recovery over the next month, regaining full cognitive function and mobility. He was discharged to spinal rehabilitation with oral trimethoprim-sulfamethoxazole for a duration of 6 months.

## DISCUSSION

Nocardial involvement of the CNS, in particular the spinal cord and meningeal layers, is exceedingly rare with only a handful of tissue and culture-confirmed cases in the literature<sup>[9–15]</sup>. We searched the literature for nocardia infection of the spinal cord and the spinal meninges and summarize the location, therapy and follow-up results in *Table 1*.

Nocardial involvement of the spinal cord occurs predominately in the immunocompromised population<sup>[7,9,10,13–15]</sup> with only one case of an isolated spinal cord intramedullary nocardial abscess in an immunocompetent patient<sup>[12]</sup>; however, there no evidence that formal immune testing was performed<sup>[8,11]</sup>. In the majority of cases, there was a co-existing pulmonary nocardial infective focus which was likely to represent the primary site prior to CNS dissemination<sup>[9,11,13,14]</sup>. However, isolated spinal cord nocardial abscesses without extra spinal involvement<sup>[12]</sup> or nocardial CNS abscesses have been reported<sup>[10,15]</sup>. Our case was interesting in that the patient had known cerebral involvement before the development of the intradural focus, raising the possibility of CSF spread from the intracerebral focus.

Spinal cord nocardial infection must be diagnosed extremely quickly as the majority of patients present with rapid evolving focal neurological symptoms, which if not treated in a timely manner can result in permanent neurological impairment<sup>[9–15]</sup>. *Stokes et al.* reported both urinary frequency and incontinence in lesions involving the cervical spine and conus medullaris, causing a partial cauda equina syndrome without perianal anaesthesia as an associated symptom<sup>[14]</sup>.

Prompt surgical decompression of intra/extradural nocardial lesions with open biopsy is the mainstay of interventional treatment.

Case	Age, sex	Primary infective focus	CNS Involvement	Culture Isolates	Treatment
Welsh et al. <sup>[9]</sup>	38; F	Pulmonary focus	Intracerebral and thoracic spine foci	<i>Nocardia asteroides</i> (pulmonary focus)	Streptomycin isoniazid, aminosalicylic acid, sulfadiazine
Yenrudi et al. <sup>[10]</sup>	34; F	Isolated CNS involvement	Multiple intracerebral, cerebellar and intramedullary C3 cervical spine foci	No growth (serological diagnosis)	Cloxacillin
Kampfl et al. <sup>[11]</sup>	63; M	Features of meningitis-headache	Intracerebral and multiple intramedullary foci	No growth (serological diagnosis)	Penicillin, chloramphenicol, oxacillin, metronidazole, ceftriaxone, fluconazole, amikacin, cotrimoxazole
Mukunda et al. <sup>[12]</sup>	52; M	Isolated intramedullary abscess	Intramedullary focus	<i>Nocardia asteroides</i> , intraspinal focus	Cotrimoxazole, imipinem-cilastatin, minocycline
Samkoff et al. <sup>[13]</sup>	79; M	Pulmonary focus	C3–C4 intramedullary spinal focus	<i>Nocardia farcinica</i>	IV trimethoprim-sulfamethoxazole for 10 days plus IV dexamethasone
Stokes et al. <sup>[14]</sup>	75; F	Pulmonary focus	Multiple intracerebral and intramedullary foci at craniocervical junction and conus focus	<i>Nocardia cyriacigeorgica</i> Intraspinal focus from bronchoscopy, no organism cultured	IV meropenem, ceftriaxone, trimethoprim and sulfamethoxazole for 11 weeks Oral trimethoprim and sulfamethoxazole for 6 month
Durmaz et al. <sup>[15]</sup>	59; M	No extra-CNS focus	Multiple intracerebral foci, intramedullary C3–T1	<i>Nocardia asteroides</i> from drained spinal abscess	Amikacin, ceftriaxone, trimethoprim and sulfamethoxazole
Present case	77, M	Intrapulmonary focus	Intracerebral and intradural extramedullary foci C3–C6	<i>Nocardia asteroides</i> (intraspinal focus)	Trimethoprim, sulfamethoxazole

F, female; IV, intravenous; M, male

Table 1: Past intradural and/or intramedullary spinal nocardiosis.

The only case of multiple surgical procedures where spinal decompression and excision of intracerebral foci were performed as two separate operations as described in *Durmaz et al.* was associated with a poor outcome for the patient, who never regained consciousness and died without being extubated post operatively<sup>[15]</sup>. Maximal medical therapy as was demonstrated in *Stokes et al.* and *Kampfl*, is associated with improvement in neurological function, with some residual weakness in the lower limbs<sup>[11,15]</sup>.

The diagnosis of a disseminated nocardial infection is inherently challenging, with the key area of difficulty being the acquisition of culture-proven nocardial species to confirm the diagnosis. An invasive approach is necessary to acquire the appropriate sample for analysis and culture of the organism as demonstrated in all culture-proven cases of nocardial infections<sup>[12–15]</sup>.

Because of the high propensity, as seen in our case series, for disseminated spread, all patients with a pulmonary focus should have formal CNS scanning with brain imaging to rule out CNS dissemination. Any new neurological symptoms or focal neurological deficits should be carefully examined, as spinal cord spread and cord compression is a very real possibility with catastrophic consequences as seen in the case reported by *Durmaz et al.*<sup>[15]</sup>

There is also significant variability in antibiotic susceptibility among nocardia species, further highlighting the importance of a culture-proven diagnosis for more directed treatment. Nocardial species are reported to be sensitive to trimethoprim-sulfamethoxazole, third-generation cephalosporins, amikacin and carbapenems<sup>[16,17]</sup>. As was the case in our patient, most cases of disseminated spinal nocardial infection required the use of two or more intravenous agents in initial management, with long-term therapy of up to 6 months in immunocompetent patients and up to 1 year in immunocompromised patients with maintenance therapy on trimethoprim-sulfamethoxazole<sup>[17]</sup>.

Interval MRI is a useful modality to assess response to treatment<sup>[17,18]</sup> with scans performed at 3-month and 9-month follow-up as in *Stokes et al.*, who demonstrated resolution of lesions radiologically, indicating good response to treatment along with clinical review at those time points<sup>[14]</sup>.

## CONCLUSIONS

Disseminated nocardiosis of a CNS brain abscess should be considered in the differential diagnosis of a spinal cord and/or spinal meningeal enhancing lesion, even in immunocompetent patients. In our patient, prompt decompressive laminectomy and open biopsy of the suspected cervical intradural extramedullary lesions lead to early identification of the organism and treatment with favourable outcome.

## REFERENCES

1. Beaman BL, Burnside J, Edwards B, Causey W. Nocardia infections in the United States, 1972–1974. *J Infect Dis* 1976;**134**:286–289.
2. Fleetwood IG, Embil JM, Ross IB. Nocardia asteroides cerebral abscess in immunocompetent hosts: report of three cases and review of surgical recommendations. *Surg Neurol* 2000;**53**:606–610.
3. Mamelak AN, Obana WG, Flaherty JF, Rosenblum ML. Nocardial brain abscess. Treatment strategies and factors influencing outcome. *Neurosurgery* 1994;**35**:622–631.
4. Kilincier C, Hamamcioglu MK, Simsek O, Hicdonmez T, Aydoslu B, Tansel O, et al. Nocardial brain abscess: review of clinical management. *J Clin Neurosci* 2006;**13**:481–485.
5. Menendez R, Cordero PJ, Santos M, Gobernado M, Marco V. Pulmonary infection with nocardia species: a report of 10 cases and review. *Eur Respir J* 1997;**10**:1542–1546.
6. Hui CH, Au VM, Rowland K, Slavotinek JP, Gordon DL. Pulmonary nocardiosis revisited: experience of 35 patients at diagnosis. *Respir Med* 2003;**97**:709–717.
7. Kageyama A, Yazawa K, Ishikawa J, Hotta K, Nishimura K, Mikami Y. Nocardial infections in Japan from 1992 to 2001 including the first report of infection by Nocardia transvalensis. *Eur J Epidemiol* 2004;**19**:383–389.
8. Marchandini H, Eden A, Jean Pierre H, Reynes J, Jumas Bilak E, Boiron P, et al. Molecular diagnosis of culture-negative cerebral nocardiosis due to Nocardia abscessus. *Diagn Microbiol Infect Dis* 2006;**55**:237–240.
9. Welsh JD, Rhoades ER, Jaques W. Disseminated nocardiosis involving spinal cord: case report. *Arch Intern Med* 1961;**108**:73–79.
10. Yenrudi S, Shuangshoti S, Pupaibul K. Nocardiosis: report of 2 cases with review of literature in Thailand. *J Med Assoc Thai* 1991;**74**:47–54.
11. Kampfl A, Auckenthaler A, Berek K, Birbamer G, Haring HP, Luef G, et al. Cerebral and spinal nocardia infection. A case report. *Wien Klin Wochenschr* 1992;**104**:174–177.
12. Mukunda BN, Shekar R, Bass S. Solitary spinal intramedullary abscess caused by Nocardia asteroides. *South Med J* 1999;**92**:1223–1224.

13. Samkoff M, Monajati A, Shapiro J. Teaching NeuroImage: nocardial intramedullary spinal cord abscess. *Neurology* 2008;**71**(3):e5.
14. Stokes MB, Reardon KA, O'Day J. Acute spinal cord compression caused by disseminated Nocardia infection involving the conus medullaris. *Clin Neurol Neurosurg* 2010;**112**:726–728.
15. Durmaz R, Atasoy MA, Durmaz G, Adapinar B, Arslantas A, Aydinli A, et al. Multiple nocardial abscess of cerebrum, cerebellum, and spinal cord, causing quadriplegia. *Clin Neurol Neurosurg* 2001;**103**:59–62.
16. Georghiou PR, Blacklock ZM. Infection with Nocardia species in Queensland. A review of 102 clinical isolates. *Med J Aust* 1992;**156**:692–697.
17. Lerner PI. Nocardiosis. *Clin Infect Dis* 1996;**22**:891–903; quiz 904–905.
18. Threlheld SC, Hooper DC. Update on management of patients with Nocardia infection. *Curr Clin Top Infect Dis* 1997;**17**:1–23.