



ATYPICAL PULMONARY METASTASIS OF PROSTATE ADENOCARCINOMA: A RARE PHENOMENON

Asma Jamil¹, Ruhma Ali¹, Amy Paige¹, Richard Miller¹, Nirav Mistry¹, Ahmed Abbas¹, Abu Tahir Taha²

¹ St Michael Medical Center, Newark, USA

² University of California, San Francisco, USA

Corresponding author: Asma Jamil **e-mail:** ajamil1@primehealthcare.com

Received: 21/03/2024 Accepted: 24/03/2024 Published: 22/04/2024

Conflicts of Interests: The Authors declare that there are no competing interests.

Patient Consent: A written informed consent from patients was obtained prior to publishing this case report.

Acknowledgements: We are extremely grateful for the love and support of our patient, and our colleagues who provided their guidance and support in the publishing of this case report.

This article is licensed under a [Commons Attribution Non-Commercial 4.0 License](https://creativecommons.org/licenses/by-nc/4.0/)

How to cite this article: Jamil A, Ali R, Paige A, Miller R, Mistry N, Abbas A, Taha AT. Atypical pulmonary metastasis of prostate adenocarcinoma: a rare phenomenon. *EJCRIM* 2024;11:doi:10.12890/2024_004494

ABSTRACT

Prostate cancer can metastasise to the lung. Most common presentations described in the literature are solitary pulmonary nodules, lymphangitic spread and, rarely, pleural effusion.

We describe a case of prostate adenocarcinoma with diffuse bilateral reticulonodular and lymphangitic pulmonary metastasis, and malignant pleural effusion while being on androgen deprivation therapy.

KEYWORDS

Prostate cancer, metastasis, adenocarcinoma, lymphangitic spread, prostate-specific antigen (PSA), lactate dehydrogenase (LDH)

LEARNING POINTS

- Lymphangitic metastasis of prostate cancer to the lung with diffuse reticulonodular infiltrate is a rare presentation.
- In chemical castration-sensitive prostate cancer, prostate-specific antigen (PSA) levels can be improving but the patient can still develop new distant metastases.

INTRODUCTION

Prostate adenocarcinoma is the most common cancer in males in the United States and is often found in the non-metastatic setting. The prognosis with metastatic prostate cancer is less favourable, although treatment options are available to control the disease for an extended period. Pulmonary metastasis is relatively uncommon. Lymphangitic pulmonary involvement in patients with prostate adenocarcinoma is extremely rare and occurs in less than

0.2% of the patient population^[1]. Androgen deprivation (hormone) therapy is the backbone of management of prostate cancer metastasis; this case involves a diffuse nodular metastasis with malignant pleural effusion while the patient is on this therapy.

CASE DESCRIPTION

A 64-year-old male with a past medical history of chronic obstructive pulmonary disease and gastroesophageal reflux



disease, hypertension, coronary artery disease and prostate cancer metastasis to the bones and lymph nodes, presented to the emergency department with the complaint of chest pain. The chest pain was sharp, non-radiating and was associated with shortness of breath. His social history was significant for heavy tobacco and alcohol use, but he stopped a year ago. He was diagnosed with prostate cancer 5 years ago and was treated with CyberKnife® at the time; he had a recurrence of cancer 9 months before, when he was found to have diffuse lymphadenopathy. A neck lymph node biopsy showed adenocarcinoma with neuroendocrine differentiation. The tumour markers were positive for prostate-specific antigen (PSA), prostate-specific acid phosphatase (PSAP) and NKX 3.1 gene, and negative for thyroid transcription factor 1 (TTF-1) and synaptophysin supporting prostatic origin. However, some tumour cells were also positive for synaptophysin suggestive of neuroendocrine differentiation of tumour. The patient was treated with monthly leuprorelin and daily enzalutamide. His response was monitored with PSA levels that showed progressive improvement from 2,874 ng/ml to 11 ng/ml, checked one month before. His vitals on admission were stable with a temperature of 36.9 °C, blood pressure 155/83–160/83 mmHg, pulse 73–99 beats per minute, respiratory rate 20 breaths per minute with O₂ saturation 90% on a 2 l nasal cannula. His body mass index was 17.20. The physical examination revealed a cachectic man in no acute distress. There were decreased breath sounds on the right posterior lung field, but no egophony. There was dullness to percussion on the right lower base; no wheezing or rales were present. There was no palpable lymphadenopathy on the examination and the remainder of the physical examination was unremarkable. Laboratory test results on admission are outlined in *Table 1*. An EKG did not reveal any ST segment changes or T wave inversion. A chest X-ray on admission showed diffuse bilateral reticulonodular opacities (*Fig. 1*). A computed tomography (CT) scan of the chest without contrast on admission showed new bilateral discrete nodules affecting all lobes (*Fig. 2-5*). There were multiple areas of ground glass opacity and consolidation in both upper and lower lung zones. Persistent centrilobular and paraseptal emphysema

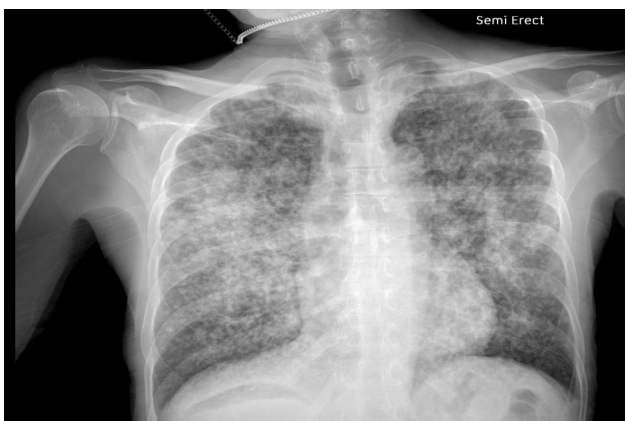

Figure 1. Chest X-ray showing diffuse bilateral reticulonodular opacities.

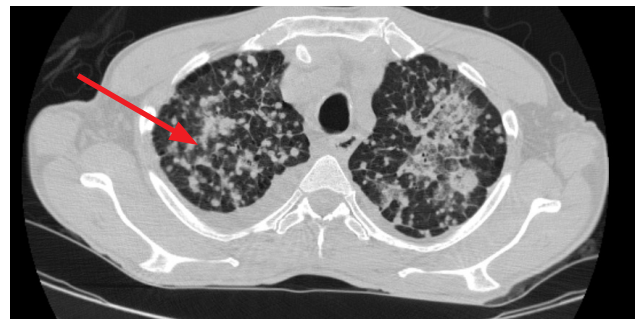

Figure 2. Arrow points to a conglomerate of discrete nodules.

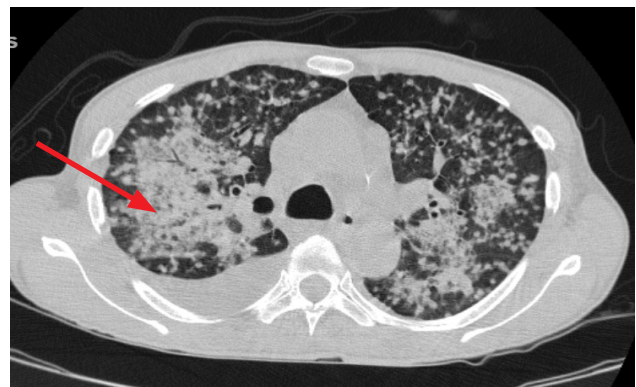


Figure 3. Arrow points to consolidation from conglomeration of nodules.

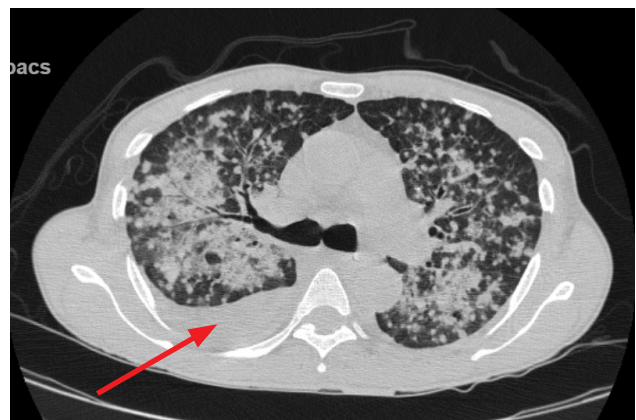


Figure 4. Arrow points towards right pleural effusion.

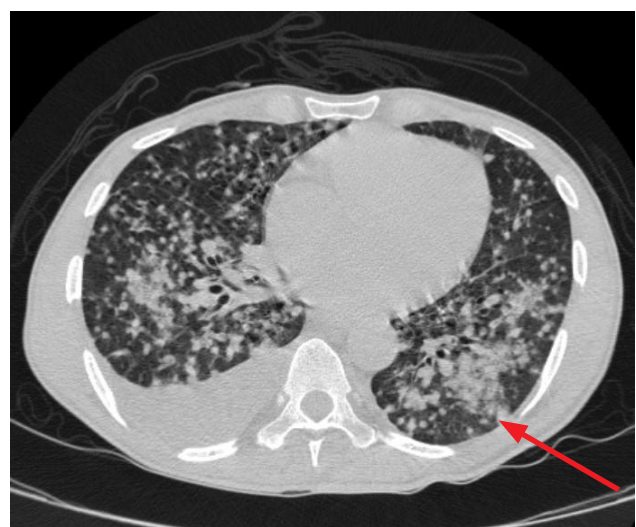
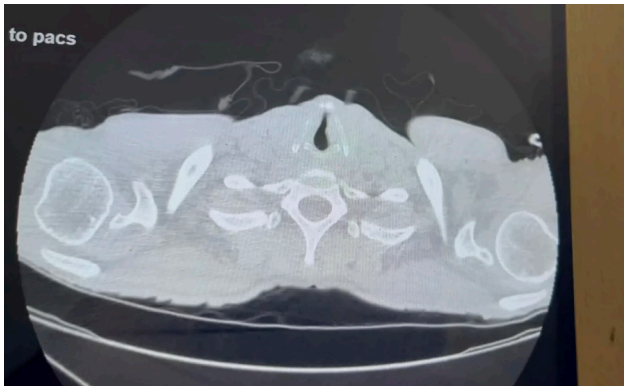


Figure 5. Arrows point towards pleural studding with multiple lung nodules.



Video 1. <https://youtu.be/zoaGM6AMISY>

was present. A 1.7 × 1.7 cm left upper lobe cavitory lesion was noted; moderate right pleural effusion was present. However, the CT scan revealed a significant decrease in supraclavicular lymphadenopathy that was noted on prior admission (Video 1).

The patient was started on empiric broad-spectrum antibiotics with cefepime and vancomycin to cover for community-acquired pneumonia given his CT findings in the setting of active malignancy. After discussion with the oncology and pulmonology team, a decision was made to perform thoracentesis. Pleural fluid analysis showed exudative fluid with high lactate dehydrogenase of 552

U/l. Pleural fluid cytology was positive for metastatic adenocarcinoma consistent with prostatic origin. The patient was discharged on home oxygen with outpatient follow-up with oncology and pulmonology, with the plan to change his chemotherapy regimen to docetaxel and enzalutamide.

DISCUSSION

Prostate adenocarcinoma is the most common cause of non-cutaneous cancer in men in the United States, with the incidence increasing in the United States and worldwide^[2]. Metastatic prostate cancer typically signifies poor prognosis. Regional lymph nodes and metastasis to the bones, specifically spinal involvement, have been reported as the most common sites of metastatic spread in prostate cancer.

Pulmonary involvement has been noted to have a high prevalence during the autopsy of patients with prostate cancer; however, it is discovered in less than 1% of the patients during their lifetime^[3]. In some cases, nodular involvement in the lung has been observed^[4], whereas pulmonary lymphangitic spread with malignant pleural effusion has rarely been reported. Here, we discuss a unique case of diffuse pulmonary infiltrates with malignant pleural effusion in the setting of hormone-sensitive prostate adenocarcinoma.

Laboratory test	Laboratory value	Reference range
Sodium	142	136–145 mmol/l
Potassium	3.1	3.5–5.3 mmol/l
Chloride	111	98–110 mmol/l
Bicarbonate	22	20–31 mmol/l
Blood urea nitrogen (BUN)	12	6–24 mg/dl
Creatinine	0.56	0.7–1.30 mg/dl
Glucose	78	70–140 mg/dl
Aspartate aminotransferase (AST)	17	10–36 U/l
Alanine aminotransferase (ALT)	18	10–49 U/l
Alkaline phosphatase (ALP)	105	46–116 U/l
Total protein	6	6.4–8.4 g/dl
Albumin	3.6	3.2–4.8 g/dl
Total bilirubin	0.6	0.2–1.2 mg/dl
Calcium	7.7	8.6–10.4 mg/dl
Lactic acid	1.1	0–2 mmol/l
Brain natriuretic peptide (BNP)	65.75	<100 pg/ml
LDL cholesterol	76	0–100 mg/dl
Prostate-specific antigen (PSA)	10.04	0–4 ng/ml
White blood cells (WBC)	12.5	4.4–11 × 10 ⁹ /l
Hemoglobin (Hgb)	12.5	13.5–17.5 g/dl
Haematocrit	37.5	38.8–50 %
Platelets	168	150–450 × 10 ⁹ /l
International normalised ratio (INR)	1.29	1–1.5
Partial thromboplastin time (PTT)	24.6	<40 seconds
C-reactive protein (CRP)	9	0–0.8 mg/dl
Procalcitonin	0.14	0–0.50 ng/ml

Table 1. Laboratory test results.

The pathogenesis of metastatic spread to the lungs occurs through the tumour embolism to the pulmonary microvasculature, followed by fluid accumulation and tissue obstruction via infiltration of the lymphatic vessels^[5]. Clinically, the disease can present with progressive dyspnoea without any inciting event. Imaging studies of the lymphangitic spread can characteristically show multiple linear densities forming a reticular pattern with a thickened bronchovascular bundle^[1]. Another radiographic pattern includes the characteristic 'tree in bud' appearance with bronchial luminal impaction in the peripheral branching airway. Our patient had multiple areas of ground glass opacification, discrete reticulonodular infiltrates and moderate pleural effusion on the CT chest scan. Thick interlobular septum and bronchovascular interstitium suggested perilymphatic disease with pleural fluid cytology positive for adenocarcinoma of prostatic origin.

A retrospective review of 91 patients with advanced prostate cancer revealed only three patients with bilateral coarse infiltrates consistent with lymphangitic spread^[4]. To our knowledge, only a few cases of lymphangitic metastasis of the prostate adenocarcinoma have been reported and surprisingly, none of them occurred in castration-resistant settings. Our patient had metastatic prostate cancer to the bone and lymph nodes. He was promptly started on aggressive systemic therapy and was noted to have improvement in the bone pain. His PSA level also responded favourably with reduction in lymphadenopathy as seen on a repeat CT scan. Nonetheless, he still developed respiratory distress due to lymphangitic as well as reticulonodular spread of the prostate cancer.

CONCLUSION

Clinicians' awareness of the possible lymphangitic spread of prostate adenocarcinoma to the lung is required for prompt diagnosis even in patients with an otherwise anticipated response to androgen deprivation therapy.

REFERENCES

1. Meyer A, Mariani RA, Nabhan C. Lymphangitic pulmonary metastases in castrate-resistant prostate adenocarcinoma. *Case Rep Med* 2012;2012:980920.
2. Hsing AW, Tsao L, Devesa SS. International trends and patterns of prostate cancer incidence and mortality. *Int J Cancer* 2000;85:60–67.
3. Knight JC, Ray MA, Benzaquen S. Malignant pleural effusion from prostate adenocarcinoma. *Respir Med Case Rep* 2014;13:24–25.
4. Morin ME, MacNealy GA, Tan A, Li YP, Engel G, Henneberry M. Hormonal manipulation of pulmonary metastases from carcinoma of the prostate. *Urol Radiol* 1982;4:23–27.
5. Gorshein E, Burger R, Ferrari A, Mayer T. Dramatic mixed response of lymphangitic pulmonary metastases in newly diagnosed prostate cancer. *Urol Ann* 2017;9:278–280.