

A Diagnosis of Inflammatory Pseudotumor of the Liver by Contrast Enhanced Ultrasound and Fine-Needle Biopsy: A Case Report

Annamaria Gesualdo¹, Rossana Tamburrano¹, Antonia Gentile², Antonio Giannini³, Giuseppe Palasciano¹, Vincenzo O Palmieri¹

¹Clinica Medica "A. Murri", Department of Biomedical Sciences and Human Oncology, University of Bari, Policlinico, Bari, Italy

²Department of Emergency and Transplantation, Pathology Section, University of Bari, Policlinico, Bari, Italy

³Radiology Division, Ospedale Di Venere, Bari, Italy

Doi: 10.12890/2016_000495- European Journal of Case Reports in Internal Medicine - © EFIM 2016

Received: 31/08/2016

Accepted: 30/09/2016

Published: 05/12/2016

How to cite this article: Gesualdo A, Tamburrano R, Gentile A, Giannini A, Palasciano G, Palmieri VO. A diagnosis of pseudotumor of the liver by contrast enhanced ultrasound and fine-needle biopsy: a case report. *EJCRIM* 2016;3: doi:10.12890/2016_000495.

Conflicts of Interests: The Authors declare that there are no competing interests.

This article is licensed under a Commons Attribution Non-Commercial 4.0 License

ABSTRACT

Inflammatory pseudotumor (IPT) of the liver is a rare, benign lesion of unclear etiology, which may be misdiagnosed as hepatocellular carcinoma, cholangiocarcinoma, secondary tumor or abscess, because of its non-specific clinical, biochemical and radiologic findings. We present the case of a 48-year-old male in whom diagnosis of liver IPT was suspected by contrast enhanced ultrasound (CEUS) and confirmed by fine-needle liver biopsy. The diagnosis is in contrast to most of the literature reports in which the diagnosis was made only based on a surgical specimen.

LEARNING POINTS

- The inflammatory pseudotumor (IPT) of the liver is a rare benign disease that may be misdiagnosed as a malignant primary or secondary tumor.
- The diagnosis of IPT may be improved by the use of contrast enhanced ultrasound (CEUS) and the fine-needle liver biopsy without surgical intervention.
- The therapy of IPT may be monitored by ultrasonography (US) and CEUS.

KEYWORDS

Liver, inflammatory pseudotumor, ultrasound, biopsy

INTRODUCTION

Inflammatory pseudotumor (IPT) is a rare, benign lesion of unclear etiology and behavior. It was first described in the lung in 1939, and subsequently in numerous organs, such as liver, lymph nodes, spleen, salivary glands and soft tissues. IPT of the liver was first described in 1953 by Pack and Backer^[1]. It is characterized by a prominent inflammatory infiltrate as the predominant cellular component. Since only a few cases have been reported in literature, it is difficult to obtain clear data regarding incidence, etiology, anatomic distribution, natural history and malignant potential of these lesions^[2].

Hepatic IPT occurs mainly in childhood and early adulthood. The male-to-female ratio ranges from 1:1 to 3,5:1. It is more common in non-European populations^[3].

The majority of IPTs of the liver appear as a solitary solid tumor, mainly arising in the right hepatic lobe^[3].

The etiology of IPT is still unclear, although a reactive inflammatory process, such as an atypical response to infections, trauma, vascular and autoimmune disorders, is thought to be involved^[2].

IPT represents an important differential diagnosis in patients with hepatic space-occupying lesions^[2] and it is often misdiagnosed as hepatocellular carcinoma, cholangiocarcinoma, secondary tumor or abscess, because of its non-specific clinical, biochemical and radiologic findings^[1-2].

Clinical symptoms of hepatic IPT include recent history of asthenia, intermittent fever, malaise, vague upper abdominal discomfort and weight loss. However, it may be asymptomatic.

Serum analyses are usually normal, or may reveal an acute phase response with an elevated ESR and/or white blood cells count. Liver function tests may reveal increased ALP and GGT^[2].

On ultrasonography, IPT reveals hypoechoic, as well as hyperechoic, solid masses. A possible diagnostic role has been proposed for contrast-enhanced ultrasounds (CEUS). On computed tomography (CT) scan, IPT appears as a low density lesion, enhanced by a contrast medium. On magnetic resonance imaging, the lesions are hypointense on T1-weighted images and hyperintense on T2-weighted images.

However, the diagnosis of IPT in most of cases requires the biopsy^[3].

IPTs are benign lesions with no evidence of malignant transformation. Occasionally the pseudotumor spontaneously regresses, but corticosteroids are successfully used^[4].

CASE REPORT

A 48-year-old white Caucasian male with a 1-month history of asthenia, malaise, vague upper abdominal discomfort and fever was admitted to hospital for diagnostic studies. The patient had never travelled outside of Europe.

His medical history revealed diagnosis of multiple sclerosis (almost four years prior, previously treated by interferon and at the moment of admission asymptomatic), diverticular disease and arterial hypertension.

The patient referred onset of intermittent fever (afternoon increase up to 39°C) with chills, whereby he was treated with cephalosporins, without obtaining clinical remission.

An abdominal ultrasound revealed hepatomegaly, multiple hepatic solid, hypoechoic lesions, the largest of which measuring 39 mm in VIII, and mild splenomegaly. An abdominal CT scan revealed three lesions in liver segments VIII, IV and VII, suggestive for abscesses or metastasis (Fig. 1A). At that point, he was referred to our clinic.

First, a CEUS was performed: the largest lesion appeared isoechoic in arterial phase and hypoechoic in portal and late phase (features suggestive for secondary hepatic nodules) (Fig. 2A). Therefore, the diagnostic hypothesis formulated was: secondary hepatic lesions of a tumor of unknown origin; infective hepatic lesions of unknown origin (possibly colon).

Laboratory tests revealed normal values of aspartate aminotransferase, alanine aminotransferase, cancer antigen (CA) 19.9, alpha-fetoprotein (AFP), CEA; gamma-glutamyl transpeptidase 56 IU/L (normal: 5–55 IU/L), erythrocyte sedimentation rate 96 (normal: 1–15), leukocytes 16.35 (normal: 3.70–9.70 x10³μL), ferritin 706 (normal: 26–388 ng/ml), and fibrinogen 806 (normal: 200–400 mg/dl).

In addition, the patient had negative serologic markers for hepatotropic viruses (HCV, HBV, Epstein-Barr virus), HIV1 and CMV. Blood cultures, coproculture and urine culture were negative, as well.

In order to exclude a possible involvement of immunological diseases, a complete study of autoimmunity (ANA, AMA, ENA, ASMA, LKM) was ruled out, with an isolated positive result for c-ANCA.

A first US-guided liver biopsy of the lesion revealed thriving inflammatory infiltrate eosinophils, histiocytes and lymphocytes and siderocytes, sometimes aggregated in microabscesses. Eosinophils were also observed around the bile ductules in portal spaces. Conclusion: no evidence of epithelial/lymphoid tumor. Aspects of pericolangite. The eosinophilic granulocyte infiltration suggested the need to exclude parasitic/disreactive/inflammatory causes.

In order to obtain further elements for the diagnosis, we performed a second US-guided liver biopsy on a different lesion. The sample showed rare hepatocyte, bile ductal trapped and slightly dysmorphic, in a context of inflammation consisting of eosinophils and neutrophils, histiocytes, lymphocytes and plasma cells. The search for iron was negative. Diagnostic conclusions: the two biopsies were comparable. The interpretation is not clear and could be compatible with chronic inflammation in partial resolution or inflammatory pseudo tumor of the liver.

In order to exclude a colorectal cancer or a colonic inflammation, a colonoscopy was performed which showed only the presence of uncomplicated diverticular disease. We concluded that the diagnosis was IPT.

Corticosteroid treatment (Prednisone 50 mg/day) was started, and follow-up via clinical, analytic and radiologic surveillance was adopted. Laboratory test results carried out 2 weeks after the beginning of the treatment showed significant improvement.

An abdominal US performed 20 days later revealed a reduction of the size of the lesions (maximum diameter 15mm). A CEUS examination showed any modification of distribution of contrast in the arterial phase and light hypoechoogenicity of lesions in both portal and parenchymal phases (Fig. 2B).

Assuming that the diagnosis of IPT of the liver was confirmed and that the lesions were progressively disappearing, the prednisone dose was tapered down to 25 mg/day.

The mass continued to shrink and symptoms resolved. Two months after the beginning of treatment, radiological examination revealed a further reduction of the residual tumor tissue, indicating good response to treatment and the need to maintain an immunosuppressive action through a low dose of prednisone (12,5mg) (Fig. 1B).

After 6 months of treatment, cortisonic therapy was stopped. US and CT revealed a complete remission of lesions.

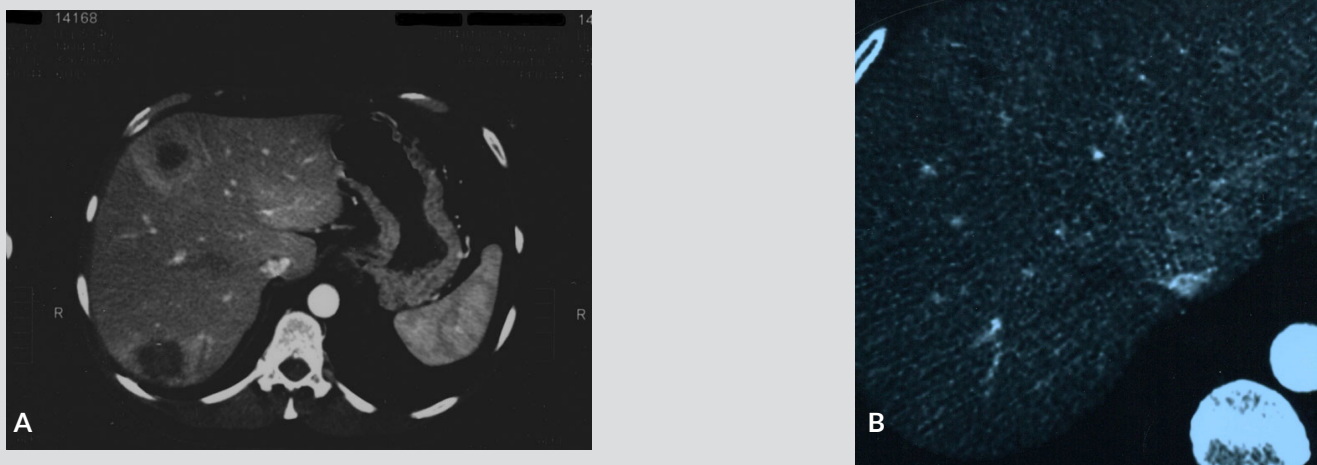


Figure 1. Abdominal Computed Tomography. A: Before treatment, the scan shows three hypodense lesions in liver segments VIII, IV and VII, with a slightly hyperdense peripheral halo during the arterial phase of examination. B: after treatment, the lesions have no contrast enhancement and are smaller in size.

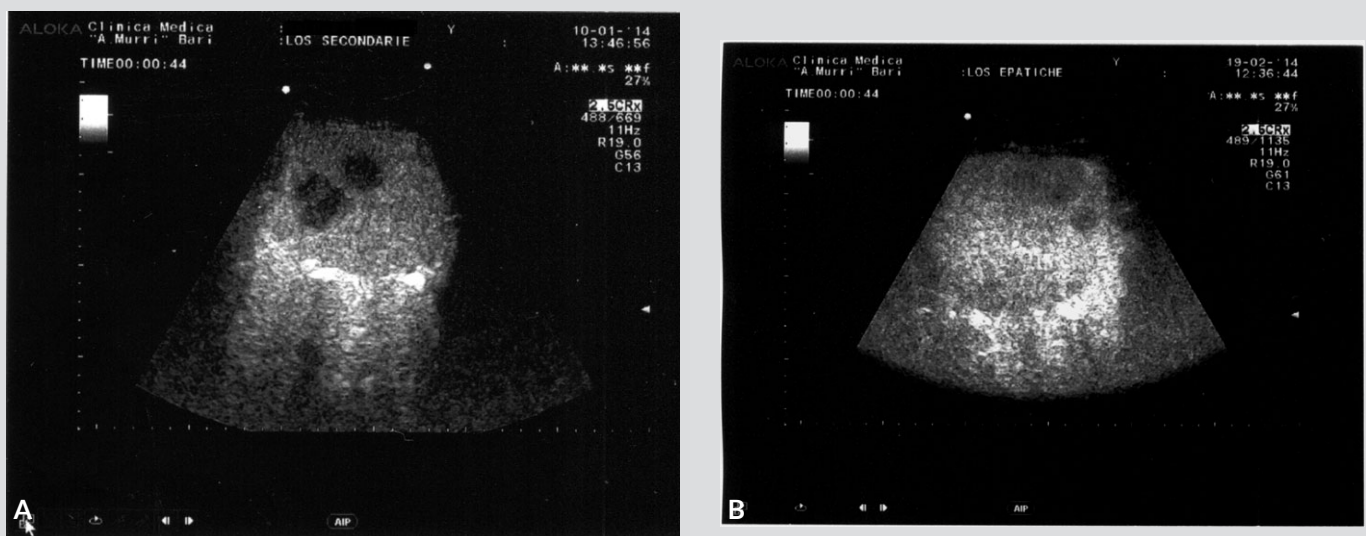


Figure 2. Contrast-enhanced ultrasound examination (CEUS). A: Before treatment, the image shows that the lesions are hypoechoic in the late phase of the examination. B: after treatment: the lesions have smaller size and appear lightly hypoechoic during the late phase of examination

DISCUSSION

We report a case of an IPT of the liver consisting of an inflammatory infiltrate composed predominantly of eosinophils and neutrophils, histiocytes, lymphocytes, plasmocytes and hepatocytes residues and newly formed bile ducts with long-term remission under corticosteroid therapy.

US imaging of IPT of the liver are not specific and are limited to the identification of solid hypoechoic space occupying lesions^[5], for whom the differential diagnosis is quite wide, ranging from primary benign tumor (cavernous angioma, nodular focal hyperplasia, adenomas) to malignant tumors (metastasis, hepatocarcinoma, colangiocarcinoma) and to focal inflammatory lesions (abscesses, IPT). The US findings need the prosecution of the diagnostic pathway on the basis of the evaluation of the clinical suspicion.

In most reports, the CT or the magnetic resonance (MR) is the second-level imaging diagnostic tool, but the sensitivity of both techniques is not good for the IPT and does not allow any diagnostic conclusion. The CT allows the exclusion of a hepatocarcinoma that has the typical aspects of hyperdense nodes in the arterial phase and hypodensity in the delayed phase^[5], but may have some limitations in the differential diagnosis of not hyperdense nodules in the arterial phase. Indeed, in our patient, the CT revealed imaging features compatible with the diagnosis of angioma, or abscess or metastatic nodules.

We think that a possible role may be reserved to the contrast-enhanced ultrasound examination (CEUS), as already suggested by Wen-Tao Kong et al.^[6].

The development of microbubble ultrasound contrast agents has overcome some of the limitations of conventional B-mode and Doppler ultrasound techniques for the liver and several other organs since these agents enable the display of the parenchymal microvasculature^[7]. The enhancement patterns of lesions can be studied during all vascular phases (arterial, portal venous, late and postvascular phases) similar to contrast enhanced computed tomography and contrast enhanced magnetic resonance imaging, but in real time and under full control of the ultrasound operator.

The real-time assessment of liver perfusion throughout the vascular phases, without any risk of nephrotoxicity, represents one of the major advantages of this technique. Diagnostic accuracy for some focal liver lesions is almost comparable to that of the CT and may be used also for the detection of the grade of necrosis of hepatic nodules that have undergone therapeutic procedures, such as radiofrequency ablation and transcatheter arterial chemoembolisation^[8].

Main limitations of CEUS are represented by the lack of panoramical view of the liver during examination, the low accuracy for lesions smaller than 1cm and the presence of hepatic steatosis.

In the case of the patient here described, the CEUS allowed physicians to exclude the possibility of angioma-like lesions and we decided to perform the execution of the biopsy based on the conclusions of this examination. Indeed, the persistence of the hypoechoic aspect of the lesions during the late phase of the distribution of the Sonovue is compatible with the diagnosis of metastasis or inflammatory nodules, but not of angioma, both capillary and cavernous.

Finally, our case confirms the need to perform the percutaneous biopsy for the diagnosis of IPT. It is noticeable that in our patient the suspicion of IPT was formulated on the basis of a fine-needle biopsy of the liver, while in most of the literature citations the diagnosis was made possible based only on a surgical specimen.

REFERENCES

1. Pack, GT, Baker HW. Total right hepatic lobectomy: report of a case. *Ann Surg* 1953;138:253-258.
2. Horiuchi R, Uchida T, Kojima T, Shikata T. Inflammatory pseudotumor of the liver: clinicopathologic study and review of the literature. *Cancer* 1990;65:1583-1590.
3. Levy S, Sauvanet A, Diebold MD, Marcus C, Da Costa N, Thieffin G. Spontaneous regression of an inflammatory pseudotumor of the liver presenting as an obstructing malignant biliary tumor. *Gastrointest Endosc* 2001;53:371-374. doi: 10.1016/S0016-5107(01)70422-1.
4. Pfeifer L, Agaimy A, Janka R, et al. Complete long-term remission of an inflammatory pseudotumor under corticosteroid therapy. *Case Rep Oncol* 2011;4:304-10. doi: 10.1159/000329415.
5. Rosa B, Moutinho-Ribeiro P, Pereira JM, Fonseca D, Lopes J, Amendoeira I, Cotter J. Ghost Tumor: An Inflammatory Pseudotumor of the Liver. *Gastroenterol Hepatol (N Y)* 2012;8:630-3.
6. Wen-Tao Kong, Wen-Ping Wang, Hao Cai, Bei-Jian Huang, Hong Ding, Feng Mao. The analysis of enhancement pattern of hepatic inflammatory pseudotumor on contrast-enhanced ultrasound. *Abdom Imaging* 2014;39:168-74. doi: 10.1007/s00261-013-0051-3.
7. Claudon M et al. Guidelines and good clinical practice recommendations for Contrast Enhanced Ultrasound (CEUS) in the liver - update 2012: A WFUMB-EFSUMB initiative in cooperation with representatives of AFSUMB, AIUM, ASUM, FLAUS and ICUS. *Ultrasound Med Biol* 2013;39:187-210. doi: 10.1016/j.ultrasmedbio.2012.09.002. Epub 2012 Nov 5.
8. Palmieri VO, Santovito D, Marano G et al. Contrast-enhanced ultrasound in the diagnosis of hepatocellular carcinoma. *Radiol Med* 2015;120:627-33. doi: 10.1007/s11547-014-0494-9. Epub 2015 Jan 20.